

# Unilateral Axillary Arch and Variations in the Axillary Vein and Intercostal Nerves: A Case Report

Sharada RAMANADHAM, Sneha Guruprasad KALTHUR,  
Shakunthala R PAI

Submitted: 14 Mac 2010

Accepted: 15 Aug 2010

Department of Anatomy, Kasturba Medical College, Manipal-576 104,  
Karnataka, India

## Abstract

Knowledge of muscular, vascular, and neural variations in the axilla is of great clinical importance, especially in mastectomies, breast reconstruction, and axillary bypass operations. In the present paper, we report unilateral variations observed in the axillary region of a male cadaver. A fibromuscular axillary arch was observed on the right side. On the same side, there was a bifurcated axillary vein; a medial cutaneous nerve of the arm passed through and later ran beneath this axillary vein. In addition, the intercostobrachial nerve was absent on the right side. The clinical significance of the variations observed and their embryological basis are discussed in this paper.

**Keywords:** axilla, axillary vein, intercostal nerve, lymph nodes, mastectomy, surgery

## Introduction

Anatomic variations may remain undetected until they are discovered during surgical intervention or after local complications have occurred. Knowledge of muscular, vascular, and neural variations in the axillary region is of clinical importance in mastectomies, breast reconstruction, and axillary bypass operations (1,2). In the present paper, we report unilateral variations in the axillary vein and the intercostobrachial nerve in a male cadaver with an axillary arch.

The axillary arch muscle (Langer's axillary arch) is an accessory muscle that extends between the pectoralis major and latissimus dorsi (3). Accessory muscle slips connected with pectoralis muscles or occurring in the axilla may have variable origin (from the latissimus dorsi or the pectoralis major) and insertion (4). The axillary arch can cause thoracic outlet syndrome and shoulder instability (5). Entrapment of the neurovascular bundle within the arch can lead to entrapment syndrome. In addition, the axillary arch hides a small group of lateral axillary nodes, which can mislead the surgeon during breast surgery (1,2).

The major blood vessels found in the axillary region are the axillary artery and the axillary vein. The axillary vein extends from the lower border of the teres major muscle to the outer border of the first rib, where it is surrounded by nerves from the

distal brachial plexus (6). The axillary vein is an alternate route for venous access during pacemaker and cardioverter defibrillator (ICD) implantation, treatment of severe burns, evaluation of central thoracic venous thrombosis caused by thoracic outlet compression, and treatment of breast carcinoma (7,8). Therefore, variations in this vein are of great clinical significance.

The nerve supply to the axillary floor is through the intercostobrachial nerve (ICBN), which is the lateral cutaneous branch of the second intercostal nerve ( $T_2$ ). It also supplies the lower third of the medial side of the arm via communication with the medial cutaneous nerve and the posterior strip of skin over the forearm (9). A second intercostobrachial nerve is often present, and it is the lateral branch of the third intercostal nerve (9). Knowledge of variations in the branching pattern of the ICBN is important for avoiding complications during mastectomies (10–12) and axillary lymph node clearance during surgery for breast carcinoma (13). Toressan et al. (14) reported that preservation of the ICBN is feasible and leads to a significant decrease in alteration of pain sensitivity of the arm without altering the total time of surgery, the number of dissected nodes, or local relapse rates.

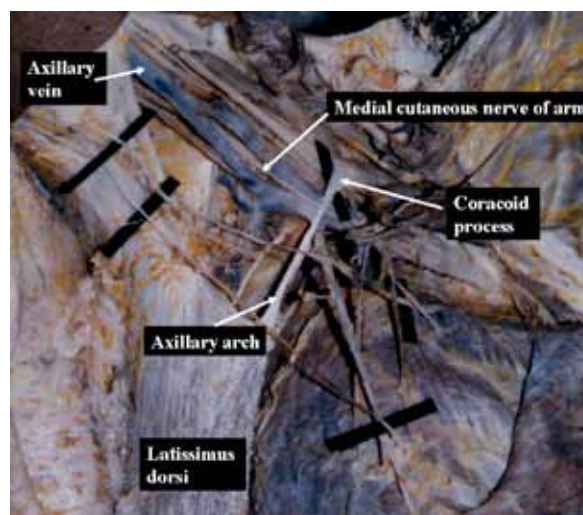
## Case Report

During routine dissection in the axillary region of a 40-year-old male cadaver, a fibromuscular band, the axillary arch, was observed on the right side. It extended from the lower border of the latissimus dorsi to the tip of the coracoid process, where some fibres mingled with the pectoralis minor. The axillary arch was 8.9 cm in length; it was partly muscular and partly fibrous. The muscular slip at the base originated from the latissimus dorsi, which was 1.6 cm wide and 3.2 cm long. The fibrous part of the arch, measuring 5.7 cm in length and 0.5 cm in width, was attached to the tip of the coracoid process (Figure 1). The latissimus dorsi had a normal nerve supply from the thoracodorsal nerve. Moreover, on the same side, the axillary vein bifurcated for a short distance and then rejoined the axilla. The medial cutaneous nerve of the arm originated from the medial cord and passed through the bifurcated part of the axillary vein, and thereafter it ran beneath the axillary vein for a short distance and then lay medial to the axillary vein. Beyond this point, the nerve had a normal course and supplied the medial aspect of skin in the lower third of the arm. However, it did not communicate with the lateral cutaneous branch of  $T_2$  (intercostobrachial nerve), which was absent. The lateral cutaneous branches of intercostal nerves  $T_1$  and  $T_3$  were seen in their respective intercostal spaces, and they supplied the axillary skin and medial aspect of the arm, respectively. The medial cutaneous nerve of the arm did not communicate with the lateral cutaneous branch of  $T_1$  and  $T_3$  (Figure 2). However, on the left side, none of these variations were observed.

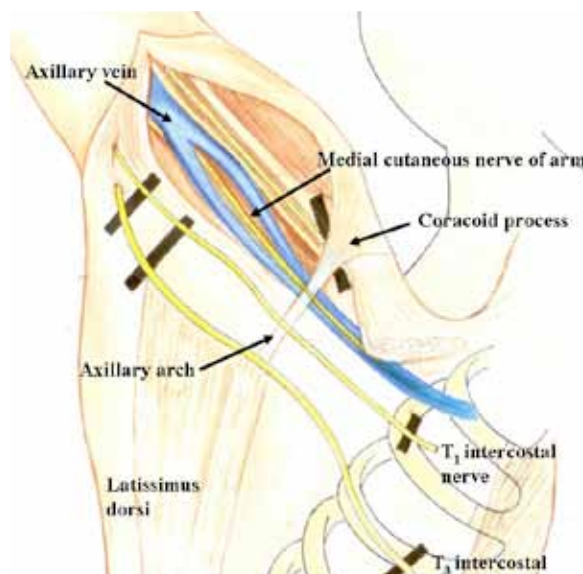
## Discussion

The axillary arch, an infrequent and often overlooked variant of the latissimus dorsi, has been recognised in 0.25%–37.5% of subjects, depending on the population studied (15). Earlier studies have reported that the muscular slip of the axillary arch may arise from the latissimus dorsi or the pectoralis major and may insert into fascia (axillary and brachial), muscles (biceps brachii, teres major, long head of triceps brachii, and pectoralis minor), or bones (coracoid process and medial epicondyle of humerus) (4,15).

In the present case, the male cadaver had a unilateral axillary arch on the right side. A major part of the axillary arch was made up of a fibrous band, which is rarely reported in the literature.



**Figure 1:** Photograph showing the fibromuscular axillary arch and bifurcated axillary vein and abnormal course of medial cutaneous nerve of arm on the right hand side



**Figure 2:** Schematic representation of variation in axillary vein and course of medial cutaneous nerve of arm

The most widely accepted view of embryological development of the axillary arch suggests that it is a remnant of the panniculus carnosus found in mammals (16). During the embryonic period, limb muscles arise in situ from the mesenchyme, which in turn is derived from the somatic layer of lateral plate mesoderm that surrounds the developing bone. As described by Cihak et al. (17), the ontogenesis of muscle has 4 fundamental phases. During phase 3, muscle primordia from different layers fuse to form a single muscle, while some muscle primordia disappear through cell death in spite of differentiated myofilaments (18). In phase 4, connective tissue elements develop and start their integration with muscle fibres. In the present case, the anomaly probably arose during phases 3 and 4, during which the majority of muscle fibres must have undergone apoptosis (during phase 3). The fibrous slip of the axillary arch might be persistent connective tissue formed between the latissimus dorsi and the coracoid process.

Identification of the axillary arch and its variations may help avoid accidental injury to axillary vessels and the brachial plexus during surgical procedures. The axillary arch can pose difficulty during sentinel lymph node biopsy because the slip stretches in the hyperabducted position and shifts the node higher (19). The latissimus dorsi is of clinical significance, especially in breast cancer surgeries, because the deep fascia surrounding the muscle is continuous anteriorly with the axillary fascia, and the nerve supply to this muscle traverses the axilla (20). The anterior edge of the latissimus dorsi marks the dorsal extent of a total mastectomy (21). Preservation of thoracodorsal nerves and vessels is of utmost importance in the preservation of muscle for reconstructive purposes (22).

Variations in the axillary vein have been reported previously. They have been observed during axillary surgeries and cadaveric dissections (23,24). A large number of invasive procedures, both diagnostic and therapeutic, use veins of the upper limb, particularly in and distal to the axillary region. The axillary vein develops in the limb bud mesenchyme during embryonic life as a dense capillary plexus that persists as a superficial capillary plexus due to different hemodynamic influences. In this plexus, some anastomoses persist to form deep vessels, while others regress. The axonal growth cones for the cutaneous nerves also traverse through the undifferentiated mesenchyme, intermingling with the developing vascular channels. The medial cutaneous nerve of the arm, which passes through

the bifurcated axillary vein, could be the result of entrapment of the persistent axonal growth cone within the venous plexus during embryological development. This variation has not been reported previously. A similar observation was reported by Hovelacque (25) in 2 cases in which it was the medial cutaneous nerve of the forearm (MCF) or a collateral branch of the MCF that perforated the axillary vein. The venous anomaly described in this case has a number of implications for medical practice. Formation of 2 narrow venous channels in place of a single vein may enhance the incidence of thrombi and emboli in cases of prolonged hyperabduction, trauma, and surgery (26).

In the present case, the lateral cutaneous branch of the first intercostal nerve and the third intercostobrachial nerve supplied the upper part of the arm independently. However, there was no contribution from the ICBN of T<sub>2</sub>. Several variations of ICBN have been reported in the literature. Cunnick et al. (27) observed 6 different variations of the ICBN during axillary dissections of 45 patients, whereas Loukas et al. (27) observed 8 different arrangements in the ICBN in 200 axillae.

Few surgeons choose to sacrifice the ICBN during segmental mastectomy because this nerve carries a T<sub>2</sub> contribution to the brachial plexus, and its preservation is important. Damage to this nerve may have additional consequences beyond the deficits described for the axillary and pectoral regions (28,29). Block dissection of axillary lymph nodes and venipuncture procedures can induce nerve injuries resulting in chronic pain in the upper limb (30). Therefore, identification of this nerve and its variations is essential for its preservation as well as the avoidance of pain and paraesthesias.

## Acknowledgements

Authors thank Mr Nagaraj Tumkur Mahalingappa, Kasturba Medical College, Manipal, for his assistance in preparing the illustration.

## Authors' Contributions

Conception and design, analysis and interpretation of the data: SR

Drafting of the article: SGK, SRP

Critical revision and final approval of the article: SGK

Administrative, technical, or logistic support: SRP

## Correspondence

Dr Sneha Guruprasad Kalthur  
 MBBS, MS Anatomy (Shivaji University)  
 Department of Anatomy  
 Kasturba Medical College  
 Manipal University, Manipal- 576 104  
 Karnataka, India  
 Tel: +91-820-2922327  
 Fax: +91-820-2571927  
 Email: sneha.guruprasad@manipal.edu

## References

- Petrasek AJ, Semple JL, McCreedy DR. The surgical and oncologic significance of the axillary arch during axillary lymphadenectomy. *Can J Surg.* 1997;**40**(1):44–47.
- Daniels IR, Della Rovera GQ. The axillary arch of Langer—the most common muscular variation in the axilla. *Breast Cancer Res Treat.* 2000;**59**(1):77–80.
- Hollinshead WH. *Anatomy for surgeons. The back & limbs.* 3rd ed. Philadelphia: Harper & Row;1982
- Bergman RA, Thompson SA, Afifi AK, Saadah FA. *Compendium of human anatomic variation. Text, atlas and world literature.* Baltimore: Urban and Schwarzenberg; 1988.
- Miguel M, Llusca M, Ortiz JC, Porta N, Lorente M, Gotzens V. The axillopectoral muscle (of Langer): Report of three cases. *Surg Radiol Anat.* 2001;**23**(5):341–343.
- Hollinshead WH. *Anatomy for surgeons.* Volume 1. New York: Hoeber-Harper; 1958.
- Decker GAG, du Plessis DJ. Lee McGregor's. *Synopsis of Surgical Anatomy.* 12th ed. Bristol: John Wright & Sons Ltd; 1986.
- Moore KL, Dalley AF. *Clinically oriented Anatomy.* 4th ed. Philadelphia: Lippincott Williams & Wilkins; 1999.
- Williams PL, Bannister LH, Berry MM, Collins P, Dyson M, Dussek JE, et al. Nervous system. In *Gray's anatomy.* 38th ed. London: Churchill Livingstone; 1999.
- Vecht CJ, Van de Brand HJ, Wajer OJ. Post axillary dissection pain in breast cancer due to a lesion of the intercostobrachial nerve. *Pain.* 1989;**38**(20):171–176.
- Paredes JP, Puente JL, Potel J. Variations in sensitivity after sectioning the intercostobrachial nerve. *Am J Surg.* 1990;**160**(5):525–528.
- Carpenter JS, Sloan P, Andrykowski MA, McGrath P, Sloan D, Rexford T, et al. Risk factors for pain after mastectomy/lumpectomy. *Cancer Pract.* 1999;**7**(2):66–70.
- Bratschi HU, Haller U. The importance of the intercostobrachial nerve in axillary lymphadenectomy. *Geburtshilfe Frauenheilkd.* 1990;**50**(9):689–693.
- Torresan RZ, Cabello C, Conde DM, Brenelli HB. Impact of the preservation of the intercostobrachial nerve in axillary lymphadenectomy due to breast cancer. *Breast J.* 2003;**9**(5):389–392.
- Loukas M, Noordeh N, Tubbs RS, Jordan R. Variation of the axillary arch muscle with multiple insertions. *Sing Med J.* 2009;**50**(2):88–90.
- Bonastre V, Rodriguez-Niedenfuhr M, Choi D, Sanudo JR. Coexistence of a pectoralis quartus muscle and an unusual axillary arch: Case report and review. *Clin Anat.* 2002;**15**(5):366–370.
- Cihak R. Ontogenesis of the skeleton & intrinsic muscles of the human hand and foot. *Adv Anat Embryol & Cell Biol.* 1972;**46**(1):5–194.
- Grim M. Ultra structure of the ulnar portion of the contrahent muscle layer in the embryonic human hand. *Folia Morphol.* 1972;**20**(2):113–115.
- Keshtgar MR, Saunders C, Ell PJ, Baum M. Langer's axillary arch in association with sentinel lymph node. *Breast.* 1999;**8**(3):152–153.
- Hammond DC. Latissimus dorsi flap breast reconstruction. *Clin Plast Surg.* 2007;**34**(1):75–82.
- Spratt JS, Donegan WL, Tobin G. Gross Anatomy of the breast. In: Donegan WL, Spratt JS, editors. *Cancer of the breast.* 5th ed. Missouri: Saunders; 2002. p. 36.
- Fisher J, Bostwick J 3rd, Powell RW. Latissimus dorsi blood supply after thoracodorsal vessel division: The serratus collateral. *Plastic Reconstr Surg.* 1983;**72**(4):502–511.
- Kutiyanawala MA, Stotter A, Windle R. Anatomical variations during axillary dissection. *Br J Surg.* 1998;**85**(3):875–876.
- Roy TS, Sharma S. Axillary vein perforation by the medial cutaneous nerve of the forearm. *Clin Anat.* 2004;**17**(4):300–302.
- Hovelacque A. *Anatomie des nerfs craniens et rachidiens et du systeme du grand sympathique chez l'homme.* Paris: Doin; 1927.
- Chang CW, Oh SJ. Medial antebrachial cutaneous neuropathy: Case report. *Electromyogr Clin Neurophysiol.* 1988;**28**(1):3–5.
- Cunnick GH, Upponi S, Wishart GC. Anatomical variants of the intercostobrachial nerve encountered during axillary dissection. *Breast.* 2001;**10**(2):160–162.
- Loukas M, Hullett J, Louis RG Jr, Holdman S, Holdman D. The gross anatomy of the extrathoracic course of the intercostobrachial nerve. *Clin Anat.* 2006;**19**(2):106–111.
- Loukas M, Joanna Grabska J, Tubbs RS, Louis RG Jr. An unusual union of the intercostobrachial nerve and the medial pectoral nerve. *Folia Morphol.* 2007;**66**(4):356–359.
- Horowitz SH. Venipuncture-induced causalgia: Anatomic relations of upper extremity superficial veins and nerves, and clinical considerations. *Transfusion.* 2000;**40**(9):1036–1040.