

Hemanth VAMANSHANKAR, Arun B NAIR, Nandakumar RAJAN

Submitted: 6 Jul 2010

Accepted: 27 Aug 2010

Department of Otolaryngology and Head and Neck Surgery, St Johns Medical College and Hospital, Bangalore, 560034, India

## Abstract

Foreign bodies are a common problem seen in otolaryngological practice. Of the reported foreign bodies, metallic foreign bodies are a rare entity. One of the least common complications of foreign body ingestion is penetration and migration. We describe a case of a migrating metallic foreign body in a 50-year-old woman with a history of accidental ingestion causing odynophagia. In the present case, the foreign body migrated extraluminally into the carotid sheath. Our review of literature revealed that few such cases have been reported.

**Keywords:** : foreign bodies, foreign-body migration, medical imaging, metals, neck, otolaryngology; head neck

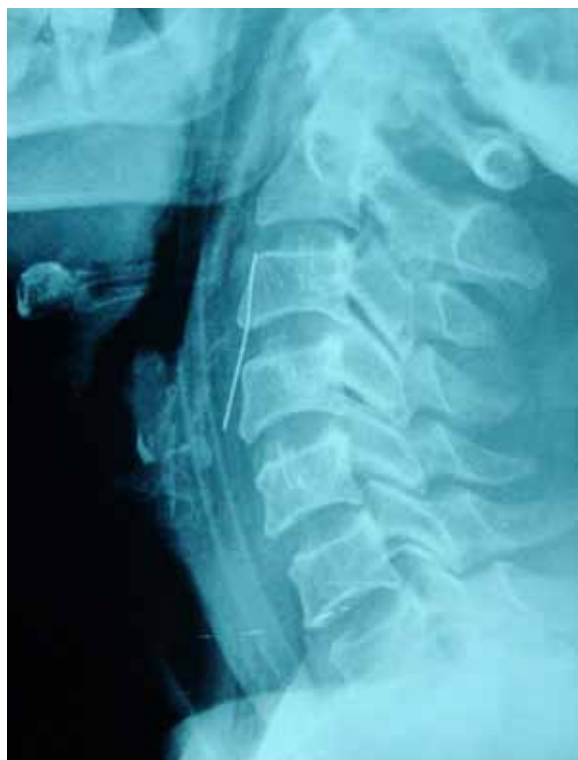## Introduction

Ingested foreign bodies (FBs) are a common problem encountered in otolaryngological practice (1). However, only a small number of FBs perforate the wall of the aero-digestive tract, and an even smaller fraction migrate extraluminally (2). Although a migrating foreign body may remain quiescent, they may cause life-threatening suppurative or vascular complications; hence, location and removal is essential. Removal of embedded FBs can be quite challenging and frustrating because location of the FB is often quite difficult.

We present a case report of a migrating metallic foreign body that was found to be present lateral to the carotid sheath, with a relevant review of the literature.

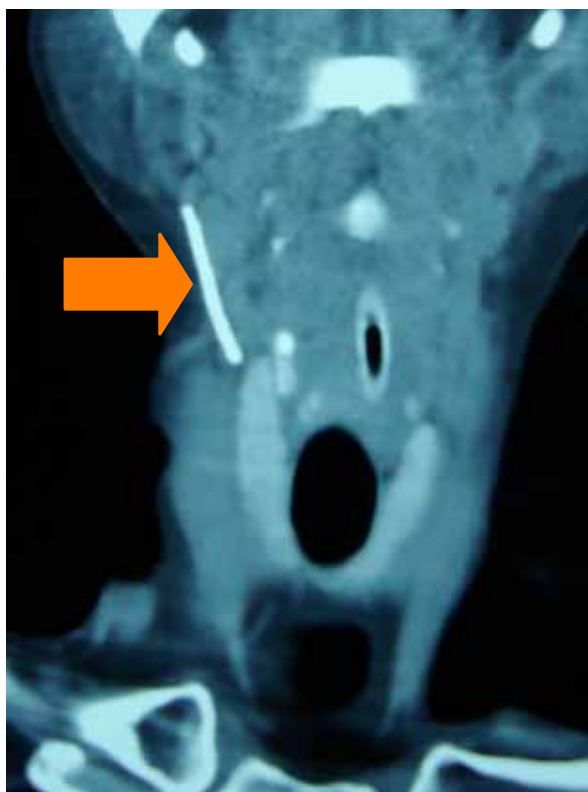## Case Report

A 50-year-old female presented to the Otolaryngology Outpatient Department, St John's Medical College and Hospital (a tertiary care centre in Bangalore, South India) with complaints of a pricking sensation in her throat for 4 days. She had been examined at a district hospital, and serial radiographs were taken, which showed a foreign body in the right retropharyngeal area. The patient was referred to our centre for further management. An initial radiograph taken at the time of admission confirmed the presence of the foreign body in the right retropharyngeal area (Figure 1).



**Figure 1:** Foreign body visualised on a radiograph at the time of admission.

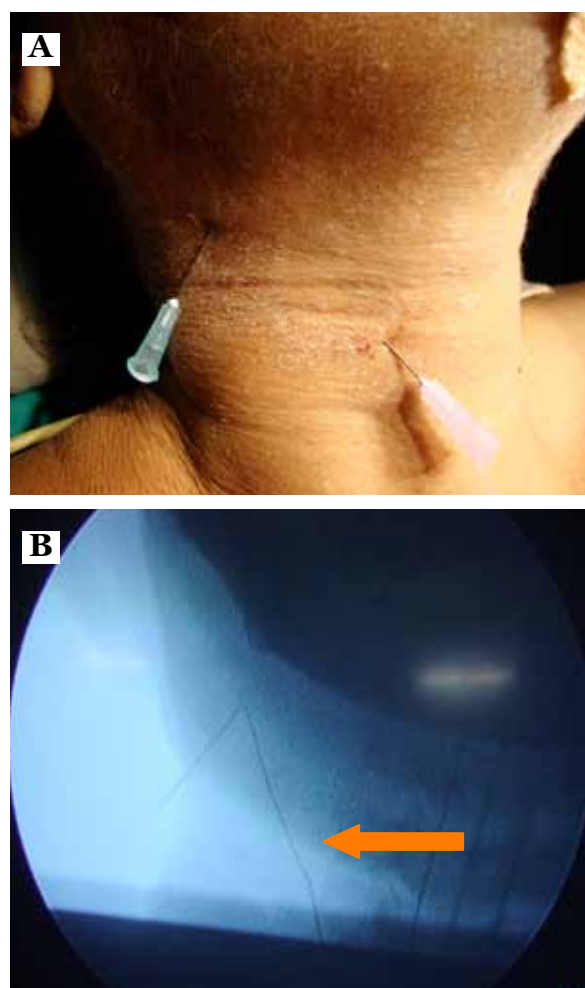
A rigid Hopkins endoscopy showed congestion in the region of the vallecula, with no foreign body (FB), casting doubt on extraluminal migration. Computed tomography (CT) of the neck with contrast showed the presence of a foreign body in the right lateral pharyngeal wall (Figure 2).



**Figure 2:** Computed tomography image showing the foreign body in the lateral pharyngeal wall.

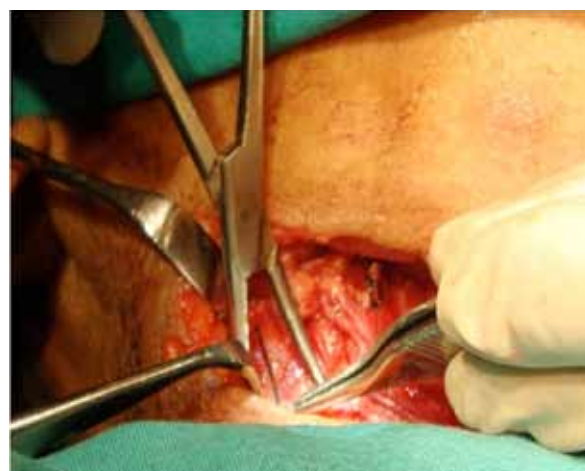A careful search was made for the foreign body under general anaesthesia with intraoperative radiographic aid. The FB could not be located; thus, an open lateral cervical approach was used. Two needles were placed below the skin in the neck, and intra-operative radiographs were taken to locate the foreign body (Figure 3). An oblique incision was made from the hyoid bone to the thyroid cartilage, and the lateral pharyngeal wall was exposed. Another attempt was made to visualise the foreign body using direct laryngoscope-assisted trans-illumination from the oral cavity. This again proved to be unsuccessful.

On further neck exploration, the foreign body (a metallic wire) was found to be embedded in the carotid sheath (Figure 4) and was removed (Figure 5). The neck wound was closed in layers, and a size 16 nasogastric tube was passed. The patient's post-operative recovery was uneventful, except for throat pain, which persisted for 2 weeks post-operatively.

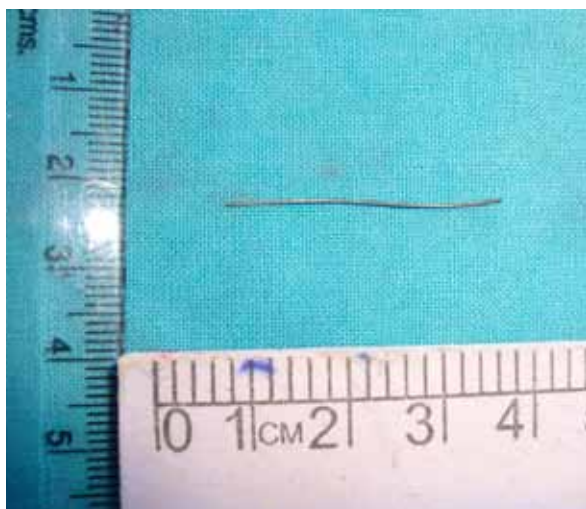


**Figure 3:** (a) Needles placed below the skin to help locate the foreign body.

(b) Foreign body with the two needles seen on an intraoperative radiograph.



**Figure 4:** Foreign body found embedded in the carotid sheath.



**Figure 5:** Foreign body post-removal.

## Discussion

Impaction of foreign bodies in the upper aero-digestive tract has been reported since early history. Foreign bodies can be lodged in the tonsils, the base of the tongue, pyriform the fossa, and the cervical oesophagus. Only rarely do foreign bodies penetrate the wall of the aero-digestive tract, and even more rarely do they migrate into the soft tissue and viscera of neck (3).

Larger and sharper FBs get stuck in the pharynx or oesophagus, causing symptoms that require their removal by oesophagoscopy. In the pharynx, FBs usually become lodged in the vallecula or lymphoid tissue, particularly the hypertrophied tonsil or tongue base. Those FBs in the oesophagus commonly remain stuck below the upper oesophageal sphincter. Foreign bodies that are sharper and those that are more horizontally oriented have a higher chance of penetrating the wall of the aero-digestive tract (4).

The possible mechanisms for penetration of foreign bodies include a combination of oesophageal peristalsis and neck movements or careless manoeuvres used when trying to remove it, for example, using fingers for balloons (4,5). Foreign bodies may also introduce bacteria into the soft tissue of the neck and cause suppurative complications such as parapharyngeal or retropharyngeal abscess (2).

A barium swallow is of limited value in locating migrated foreign bodies but can be useful in detecting oesophageal leaks (5). The most commonly used tool for foreign body identification is radiography of the soft tissues of the neck. However, images of the foreign body

and calcified cartilage of the upper airway may overlap, making location of the foreign body difficult. Thus, radiographs lack sensitivity in diagnosis (2,6). A CT scan of the neck utilising 1-mm cuts is the investigative method of choice. CT scans are invaluable in confirming the exact location of the foreign body and its relationship to the vital structures in the neck.

However, CT scans are not without their drawbacks. The soft tissues of the neck are mobile in relation to the bony and cartilaginous structures; thus, at the time of surgery, the foreign body may not be situated exactly as where it is seen in the CT, as in our case (1,5).

Direct laryngoscopy may be done for confirmation. A finding of oedema, laceration or ulceration on direct laryngoscopy should raise the level of suspicion of a penetrating foreign body (2). Exploration and removal of the foreign body via an external approach is recommended if the foreign body is confirmed to be extraluminal. Surgery may be supplemented with intraoperative radiography for accurate location of the foreign body. However, due to their poor image quality, intraoperative radiographs are not routinely used, but they come in handy as a last resort in cases in which the foreign body cannot be found after an extensive search (2).

Foreign body fixation to organ walls may lead to perioesophagitis or peripharyngitis, which can result in an abscess. Perforation may lead to fever, chest pain, subcutaneous emphysema, dyspnoea, and dysphagia. Migrating foreign bodies may rupture large vessels such as the carotid or aorta, and foreign bodies can damage neighbouring organs such as the thyroid gland. In some cases, the long duration of symptoms may be the only hint of the presence of an intraluminal foreign body (4).

## Conclusion

Our case highlights the need for a high index of suspicion to detect perforation and migration of an ingested foreign body into the soft tissues of the neck. Prompt diagnosis is needed to prevent the high morbidity that can occur in such cases. The majority of the upper aero-digestive foreign bodies are intraluminal and can be removed by endoscopy; therefore, it is cost effective to do CT scans in cases of foreign bodies that could not be located and removed endoscopically or in which the symptoms have persisted for long duration. A systemic approach to neck exploration via an external approach, with the use of intraoperative radiography, will decrease the chances of an unsuccessful exploration.

## Authors' Contributions

Conception and design: HV  
Drafting of the article: ABN  
Final approval of the article: NR

## Correspondence

Dr Arun B Nair  
DLO (Rajiv Gandhi University of Health Sciences)  
Department of Otolaryngology  
St Johns Medical College and Hospital  
Bangalore 560034  
India  
Tel: +91 80 22065346  
Fax: +91 80 25530070  
Email: drarunnair@gmail.com

## References

1. Chung SM, Kim HS, Park EH. Migrating pharyngeal foreign bodies: A series of four cases of saw-toothed fish bones. *Eur Arch Otorhinolaryngol*. 2008;**265**(9):1125-1129.
2. Sreetharan SS, Prepageran N, Satwant S. Unusual migratory foreign body in the neck. *Singapore Med J*. 2004;**45**(10):487-488.
3. Al-Sebeih K, Volvoda M, Sobeih A, Al-Sihan M. Perforating and migrating pharyngoesophageal foreign bodies: A series of 5 patients. *Ear Nose Throat J*. 2006 Sep;**85**(9):600-603.
4. Mamede RC, Amaral F, Raimundo DG, Freitas LC, Ricz HM, Mello-Filho FV. Do foreign bodies migrate through the body towards the heart? *Braz J Otorhinolaryngol*. 2009;**75**(2):195-199.
5. Lu PKS, Brett RH, Aw CY, Singh R. Migrating Oesophageal Foreign Body—An Unusual Case. *Singapore Med J*. 2000;**41**(2):77-79.
6. Masuda M, Honda T, Hayashida M, Samejima Y, Yumoto E. A case of migratory fish bone in the thyroid gland. *Auris Nasus Larynx*. 2006;**33**(1):113-116.